

Spontaneous neoplasia in the western clawed frog *Xenopus tropicalis*

Makoto Suzuki¹, Takeshi Igawa¹, Nanoka Suzuki¹, Hajime Ogino¹ and Haruki Ochi^{2§}

¹Amphibian Research Center, Hiroshima University

²Institute for Promotion of Medical Science Research, Yamagata University, Faculty of Medicine

§To whom correspondence should be addressed: harukiochi@med.id.yamagata-u.ac.jp

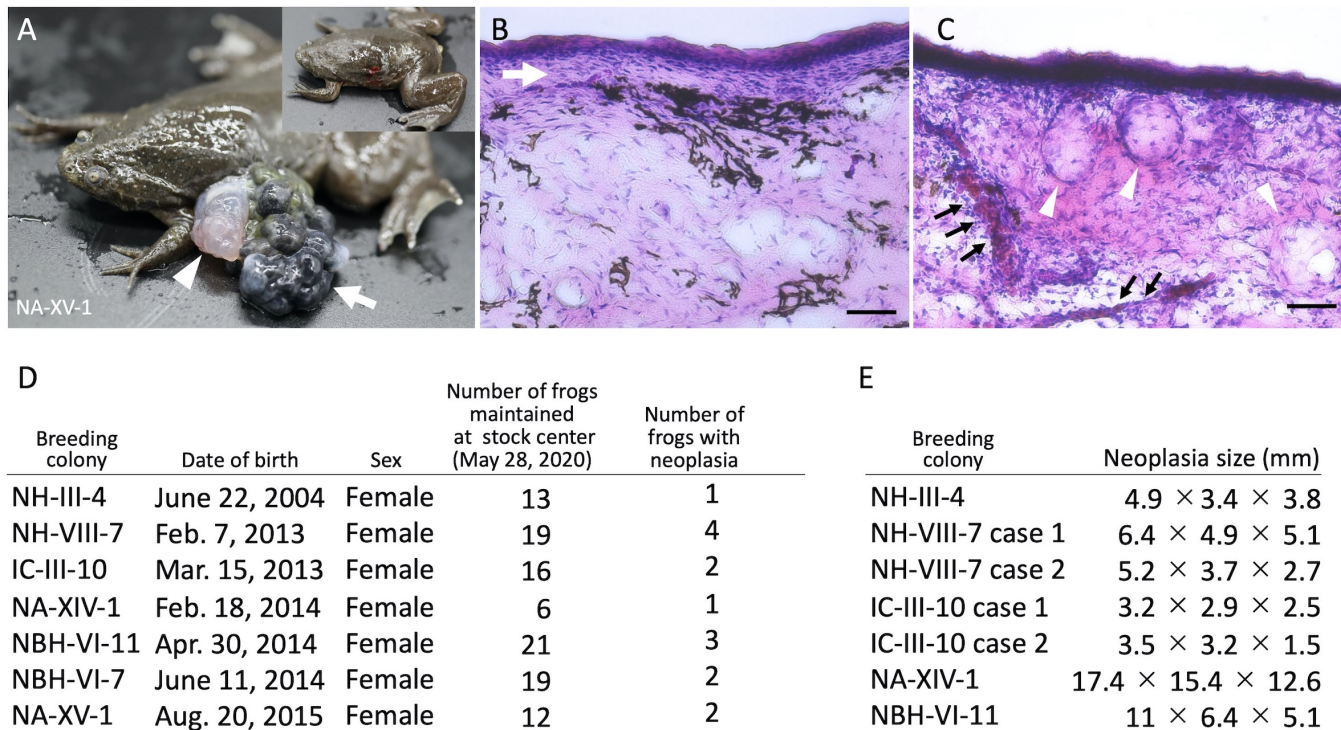


Figure 1. : (A–C) Representative images of spontaneous neoplasia in *Xenopus tropicalis*. (A) External morphology of the neoplasia. The arrow indicates the black stone-like nodules, and the arrowhead indicates the white-red nodules. The upper right panel depicts the frog for which the neoplasia was resected. (B) The layered structure in the black stone-like nodules. Hematoxylin–eosin (HE) staining of a histological section of the black stone-like nodule. The white arrow indicates the layered structure. Scale bar indicates 50 μ m. (C) The cyst-like structures and blood vessels in the white-red nodule. HE staining of a section of the white-red nodule. The white arrowheads indicate cyst-like structures and the black arrows blood vessels. Scale bar indicates 50 μ m. (D) A table showing the number of frogs with neoplasia in each colony. Regarding colony names, the first 2–3 alphabets indicate the strain names, the following Greek numbers indicate the inbred generations, and the Arabic numbers (with case numbers) indicate the colony identifiers. Most of the frogs maintained at the stock center were shipped to users as animal resources, and the remaining frogs as of May 28, 2020, were subjected to this analysis. (E) A table showing the size of neoplasia; the size was determined by measuring diameters at large and small ends, and the height above the skin surface for each neoplasia.

Description

Xenopus tropicalis is an excellent model organism for studies on vertebrate development and regeneration (Horb *et al.*, 2019) and is also useful for the study of tumor formation (Van Nieuwenhuysen *et al.*, 2015; Naert *et al.*, 2016). Spontaneously occurring neoplasia in amphibians have been reported, such as in *X. laevis*, *Rana pipiens*, and *Andria japonicus* (McKinnell *et al.*, 1968; Meyer-Rochow *et al.*, 1991; Kawasumi *et al.*, 2012). In *X. laevis*, one of 4,000 frogs (a 2.5–3-year-old female), which were maintained in artificial outdoor ponds, displayed renal adenocarcinoma without other developmental disorders, indicating that the tumor formation was quite rare in *X. laevis* (Meyer-Rochow *et al.*, 1991). In contrast to *X. laevis*, 3.66 % of *R. pipiens* in the wild heterogeneous populations had renal adenocarcinoma (McKinnell *et al.*, 1968), which was experimentally induced by herpesvirus (Granoff, 1973). Currently, there are no reports of spontaneous neoplasia in *X. tropicalis*, although recently developed genome editing technologies such as TALEN and CRISPR/Cas9 offer opportunities to induce neoplasia by simple disruption of tumor suppressor genes (Van Nieuwenhuysen *et al.*, 2015; Naert *et al.*, 2016), which

would allow modeling of human cancer in this species. The spontaneously occurring neoplasia in *X. tropicalis* could provide excellent opportunities to understand how the genetic background of this species influences the neoplasia phenotypes in combination with disruption experiments of tumor suppressor genes.

The National Bioresource Project (NBRP) of *X. tropicalis* in Japan has successfully developed the four highly inbred wild-type strains, Nigerian A (NA), Nigerian H (NH, previously named Yasuda), Nigerian BH (NBH, previously named Golden), and Ivory Coast (IC) (Igawa *et al.*, 2015). These strains are available for international research communities upon request. We found spontaneous neoplasia formation in the frog stocks at the NBRP (Figure 1). Analysis of frogs from seven colonies with different genetic backgrounds and chronological ages (16, 7, 6, or 5 years) identified neoplasias formed in various parts of the body, including the dorsal side, ventral side, dorsal head, dorsally on limbs, and eye (Figure 1D). Almost all frogs had a single site of neoplasia; just one frog from the NBH-VI-11 colony had multiple sites of neoplasia. The neoplasias of *X. tropicalis* could be divided into two types: black stone-like nodules (Figure 1A, white arrow) and white-red nodules (Figure 1A, white arrowhead). Most of the frogs were harboring only the black stone-like nodules, although a few frogs were harboring both types of nodules simultaneously (Figure 1A). Previous studies have reported that the histological analysis of amphibian and reptile neoplasias revealed the renal mass in *A. japonicus* exhibiting trabecular pattern and the epidermal mass in the *Furcifer pardalis* consisting of concentric keratin material (Kawasumi *et al.*, 2012; Meyer *et al.*, 2019). Histological analysis of *X. tropicalis* neoplasia using hematoxylin–eosin (HE) staining showed that melanocytes were enriched in the black stone-like nodules and that a layered structure was present (Figure 1B, white arrow). In contrast, cyst-like structures and blood vessels were present in the white-red nodules (Figure 1C, white arrowheads and black arrows, respectively). We then measured the neoplasia size (Figure 1E). Two frogs from the NA-XIV-1 colony had a large neoplasia, over 17 mm at the large end, over 15 mm at the small end, and over 12 mm in height (Figure 1E). The average length of the neoplasia was 7.3 mm at the large end, 4.1 mm at the small ends, and 3.5 mm in height. Therefore, it will be of interest if the frequency and size of neoplasia vary among the inbred strains on disruption of tumor suppressor genes via genome editing.

Methods

[Request a detailed protocol](#)

Neoplasias were fixed with 4% paraformaldehyde in phosphate-buffered saline (PBS) overnight at 4°C and were successively washed with PBS containing 0.1 % Tween 20. Fixed neoplasias were frozen in Optimum Cutting Temperature Compound, and cryosectioned with a thickness of 10 µm. Sections were stained with HE by a standard method. Each slide was photographed under a Zeiss Axio Vert. A microscope using an AxioCam MRc digital camera.

Reagents

X. tropicalis strains used in this experiment were maintained at the Amphibian Research Center, Hiroshima University. All treatment procedures for *X. tropicalis* were approved by Yamagata University Animal Research Committee (#310300). For HE staining, we used the following reagents: Mayer's hematoxylin solution and 1% eosin Y solution (FUJIFILM Wako Pure Chemical Corporation, Osaka, Japan), Tissue-Tek optimum cutting temperature compound (Sakura Finetek, Tokyo, Japan).

Acknowledgments: *Xenopus tropicalis* was provided by Hiroshima University Amphibian Research Center through National BioResource Project (NBRP) of AMED under Grant Number JP19km0210085.

References

- Granoff, A., 1973 Herpesvirus and the Lucke Tumor. *Cancer Res.*, 33: 1431-1433. PMID: 4578074.
- Horb M., M. Wlitzla, A. Abu-Daya, S. McNamara, D. Gajdasik, et al., 2019 *Xenopus* resources: Transgenic, inbred and mutant animals, training opportunities, and web-based support. *Fr. Physiol.* 10:1-10. DOI: 10.3389/fphys.2019.00387 | PMID: 31073289.
- Igawa T., A. Watanabe, A. Suzuki, A. Kashiwagi, K. Kashiwagi, et al., 2015 Inbreeding ratio and genetic relationships among strains of the western clawed frog, *Xenopus tropicalis*. *PLoS ONE.*, 10: e0133963. DOI: 10.1371/journal.pone.0133963 | PMID: 26222540.
- Kawasumi, T., T. Kudo, Y. Une, 2012 Spontaneous nephroblastoma in a Japanese giant salamander (*Andrias japonicus*). *J. Vet. Med. Sci.*, 74, 673-675. DOI: 10.1292/jvms.11-0477 | PMID: 22198058.
- McKinnell R. G., B. K. McKinnell, 1968 Seasonal fluctuation of frog renal adenocarcinoma prevalence in natural populations. *Cancer Res.* 28: 440-444. PMID: 5640863.

8/31/2020 - Open Access

Meyer-Rochow V. B., M. Asashima, S. D. Moro, 1991 Nephroblastoma in the clawed frog *Xenopus laevis*. J. Exper. Ani. Sci., 34: 225-228. PMID: 1667587.

Naert T., R. Colpaert, T. Van Nieuwenhuysen, D. Dimitrakopoulou, J. Leoen, et al., 2016: CRISPR/Cas9 mediated knockout of *rb1* and *rbl1* leads to rapid and penetrant retinoblastoma development in *Xenopus tropicalis*. Sci Reports. 6: 1-10. DOI: 10.1038/srep35264 | PMID: 27739525.

Van Nieuwenhuysen, T., T.Naert, H. T. Tran, G. Van Imschoot, S. Geurs, et al., 2015 TALEN-mediated *apc* mutation in *Xenopus tropicalis* phenocopies familial adenomatous polyposis. Oncoscience. 2: 555-566. DOI: 10.18632/oncoscience.166 | PMID: 26097888.

Meyer, J.; Kolodziejek, J.; Häbich, A. C.; Dinhopf, N.; Richter, B., 2019: Multicentric Squamous Cell Tumors in Panther Chameleons (*Furcifer pardalis*). *Journal of Exotic Pet Medicine.*, **29**, 166–172.

Funding: This work was supported by Grants-in-Aid for Scientific Research from the Japan Society for the Promotion of Science (JSPS) and AMED (Grants nos. 19K06672, 17KT0049 to H. Ochi and 19K06689, JP18km0210085 to H. Ogino).

Author Contributions: Makoto Suzuki: Formal analysis, Resources. Takeshi Igawa: Resources. Nanoka Suzuki: Resources. Hajime Ogino: Resources, Funding acquisition, Writing - original draft. Haruki Ochi: Conceptualization, Formal analysis, Investigation, Writing - original draft, Funding acquisition.

Reviewed By: Anonymous

History: Received June 24, 2020 **Revision received** July 28, 2020 **Accepted** July 28, 2020 **Published** August 31, 2020

Copyright: © 2020 by the authors. This is an open-access article distributed under the terms of the Creative Commons Attribution 4.0 International (CC BY 4.0) License, which permits unrestricted use, distribution, and reproduction in any medium, provided the original author and source are credited.

Citation: Suzuki, M; Igawa, T; Suzuki, N; Ogino, H; Ochi, H (2020). Spontaneous neoplasia in the western clawed frog *Xenopus tropicalis*. microPublication Biology. <https://doi.org/10.17912/micropub.biology.000294>